

Wounds and Injuries of the Soft Tissues

To maximize the preservation of life and minimize the attendant morbidity of battle wounds, the surgeon attempts to localize or isolate the deleterious effects of injury and to optimize healing. This objective is best accomplished by removal of all foreign material and detached or severely disrupted muscle from the wound, by the establishment of open drainage of the wound's recesses, and by maintaining adequate capillary perfusion of the injured tissues. Early institution of systemic antibiotic therapy plays more than an ancillary role in the management of these contaminated war wounds. If these management objectives are achieved, the risk of further local tissue destruction and systemic invasion by pathogenic micro-organisms is reduced to a minimum.

The emphasis of this chapter is on the management of damaged muscle. Surgical management of other soft tissue and bone injuries is dealt with in other chapters. Two separate mechanisms are responsible for the injury caused by the passage of missiles through tissues. As the projectile punches through muscle, it destroys the tissue in its direct path by crushing it. Temporary cavitation forces, which present about one millisecond after passage of the projectile, stretch the tissues adjacent to the permanent missile track and result in additional injury or destruction.

Crushed Muscle: The amount of crushed muscle resulting from a single bullet or single fragment is closely related to the presenting cross-sectional area of the projectile. The gross anatomy of muscle will be much more severely disrupted by multiple penetrating projectiles striking in close proximity to each other, as is the case with explosive device injuries, deforming or fragmenting rifle projectiles, or any rifle projectile that strikes bone. Some remnants of muscle crushed by penetrating **pro-**

jectiles will generally be seen as a frayed edge along the missile track. Detached pieces of muscle, partially detached muscle flaps, and muscle islands surrounded by perforations should be regarded as nonviable. They would most likely act as foreign bodies that will potentiate infection in an already contaminated wound.

Stretched Muscle: Temporary displacement of muscle by cavitation (see Chapter II) can cause petechial hemorrhages from torn small vessels (contusion), thrombosis of other small vessels, and patchy broken muscle fibers. Cavitation follows the path of least resistance, which is most often to separate muscle between parallel fibers and bundles. Gross radial splits are sometimes seen in muscle but not nearly to the extent that they are seen in skin. Although both bullet yaw and bullet deformation appreciably increase the dimensions of both the permanent and the temporary cavities, the effects of bullet fragmentation are by comparison devastating, and may result in an injury that is multiplied by several orders of magnitude in muscle that has been weakened a millisecond earlier by the creation of multiple radial fragment tracks.

DEBRIDEMENT

Where one draws the line in excising muscle surrounding a missile path has been the subject of intense debate in wound ballistics. The 5th CINCPAC War Surgery Conference (Tokyo 1971) stated "...the surgeon must choose between leaving tissue of questionable viability or causing morbidity by removing viable and functional tissue." Most other opinions of the past two decades have held that "complete excision of all devitalized tissue is mandatory," "bold removal of all devitalized muscle is imperative" (NATO Handbook, 1975), and that deformity or dysfunction resulting from such "bold" operations is justified.

Development of life-threatening gas gangrene is the complication most often cited to justify recommendations of "radical debridement" or wide excision of muscle. Of 224,080 wounded in France in WW I, those with soft tissue injury and no bone fracture developed gas gangrene in only 1.0% of cases and less than half of these were fatal. A streptococcal bacteremia was by far the most common cause of death. Many of the less than 0.5% of the deaths attributed to clostridia were suspected to have been due,

in reality, to undetected **streptococcus**. Streptolysin, excreted by the virulent Streptococcus species, breaks down the fibrin that has been deposited by the body in its attempt to wall off collections of pathological bacteria. This made generalized streptococcal spread impossible to control in the pre-antibiotic era. Since the discovery of antibiotics, streptococcal bacteremia has all but disappeared from the battlefield because *of antibiotics*, a fact overlooked by those who suggest that antibiotic therapy is only an ancillary measure in the management of combat wounds.

Debridement should be rational rather than radical. The recommendation is not to excise the wound to the extent that viable muscle is intentionally excised circumferentially, but rather to open the wound such that drainage is assured, while at the same time excising that muscle which is severely damaged or disrupted and therefore devitalized. The surgeon must aggressively incise the wound, but should not empirically excise tissue more widely than clinical judgment would normally dictate. It should be borne in mind that debridement of the wound is intended to relieve excessive tension within the wound, to rid the wound of dead tissue and massive hematoma, and to provide excellent drainage. Some would say that the relief of tension is the single most important element of wound debridement.

WOUND DYNAMICS

From the time a wound is inflicted until healing is complete, the surrounding area is in a state of constant change. In the first few hours after an extremity is exposed to the violent temporary cavity stretch of the AK-74 wound, a marked vasoconstriction of these tissues is revealed by skin blanching for a distance of 6-8 cm from the skin edges. Marked hyperemia appears around the blanched area and gradually encroaches upon it, eventually replacing it entirely in about four hours. Although less dramatic than the skin changes, increasing perfusion of muscle surrounding the missile path has been clearly demonstrated for up to 72 hours after wounding.

Since blood flow in the muscle around the projectile path is changing it is difficult at best for the surgeon, at any point in time, using any set of guidelines, to be certain of excising only (but all **of**) the nonviable muscle, and not viable muscle. Writings in the past two decades have demanded this judgment of our young

surgeons when even the most experienced combat surgeon was not always certain. This was demonstrated in the Vietnam conflict when some wounds, which were treated in accordance with the conventional "4 c" guidelines (color, contraction, consistency, circulation) were noted on arrival at another hospital, a few days later, to have obviously necrotic muscle. Some surgeons at this higher echelon of care concluded that the initial debridement had been done improperly. The 5th CINCPAC War Surgery Conference in 1971 corrected that misconception by stating that the later appearance of necrotic tissue in a wound "does not necessarily mean that the original debridement was improperly done," but rather was the result of the transitory dynamics of wound physiology at the time of the original debridement.

From a practical standpoint, the question is not whether or not to excise devitalized tissue, for there is good agreement here, but rather how to accurately differentiate muscle that is injured but will heal from that muscle which is nonviable and should be excised. Generations of surgeons have accepted the assumption that nonviable muscle can be identified by its dark color, its "mushy" consistency, its failure to contract when pinched with forceps, and the absence of brisk bleeding from a cut surface (the 4c's). The surgeon inclined to err in the direction of radical excision should bear in mind that in all studies in which animals were kept alive long enough to observe and measure wound healing objectively or to evaluate the pathology around the missile wound microscopically, there was less lasting tissue damage than estimated from observation of the wound in the first few hours after the wound was inflicted. The foregoing notwithstanding, the surgeon must base judgment on decisions made at the table at the time of operation. The majority of combat surgeons continue to utilize the 4 c's as guidelines and consider it prudent to excise muscle of questionable viability.

TREATMENT RECOMMENDATIONS

Establish an adequate blood level of penicillin or an antibiotic with a similar spectrum as soon as possible after wounding. Make generous incisions of the wound to relieve mechanical pressure and establish open drainage. Remove easily-accessible foreign bodies and detached pieces of muscle, and irrigate the wound

copiously. The wound track is then inspected and any additional muscle whose gross architecture is severely disrupted is excised. At the conclusion of the procedure, complete hemostasis must be achieved to preclude the subsequent development of collections within the wound that would impede capillary perfusion of borderline tissues. The technique is shown in Figure 24.

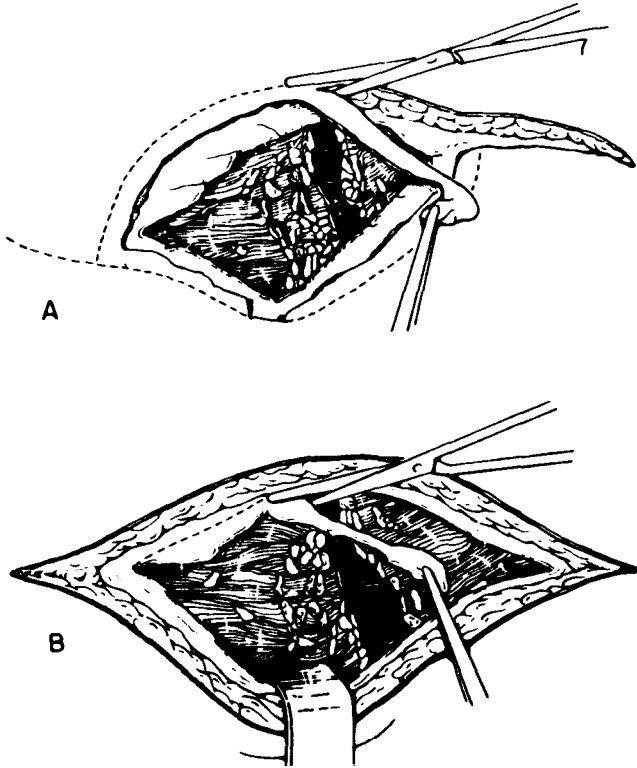


FIGURE 24.-Technique of debridement in soft-tissue wounds. A. Line of incision and excision of traumatized skin. B. Excision of traumatized fascia.

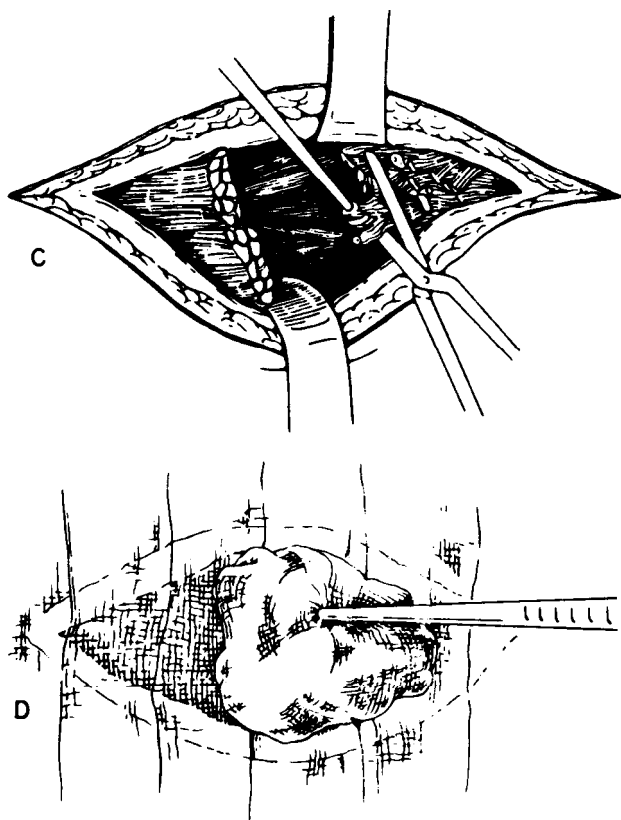


FIGURE 24.-Continued. C. Excision of devitalized muscle D. Technique of wound dressing.

1. Excise entrance and exit wounds with a narrow margin of skin oriented parallel to the underlying muscle fibers. This excised skin margin should include, in continuity, the underlying subcutaneous tissue. These incisions should be generous, such that optimal surgical exposure and adequate subsequent drainage will be achieved.

2. Through these openings, generously incise the fascia parallel to the muscle fibers in both directions. The underlying muscle surrounding the missile tract should be opened in the direction of its fibers to the degree necessary to achieve exposure adequate to

inspect the track, remove foreign bodies, and excise non-viable muscle. These maneuvers are performed at both the wound of entry and the exit wound. The muscle surrounding the central portion of the track can usually be dealt with through the entry and exit wounds. For example, a mid-thigh, through-and-through wound of the soft tissues can generally be surgically managed by working through the excised and extended wounds of entry and exit. This approach precludes the necessity of cutting across good muscle groups as is generally the case when one elects to connect the two wounds. Appropriate drainage of war wounds is often easier said than done. Liberal incisions tend to facilitate drainage from the wounds deeper recesses. Whereas excision of skin, fascia, arteries, nerves, veins, and bone is conservative, the excision of muscle should be more liberal.

3. As a dressing, dry sterile gauze should be laid lightly in the wound. This should be no more than a wick. In no case should gauze be "packed" into the wound since this additional pressure can cause necrosis of any tissue that already has its blood supply partially compromised.

4. The single most important principle in the management of battle wounds is their nonclosure following debridement. The surgeon must not give in to the temptation to primarily close certain "very clean appearing" war wounds. Such closure is ill advised and inappropriate and can only be condemned. All wounds must be left widely open with the following exceptions:

- a. Sucking chest wounds
- b. Joint capsules
- c. Wounds of the dura
- d. Some head and neck wounds; however, with severe contamination it may be safer to leave these open.

5. The delayed primary wound closure is usually performed in a communication zone hospital 4-10 days after debridement, but occasionally may be performed at the forward hospital when evacuation has had to be delayed. The indication for delayed primary closure is the clinically clean appearance of the wound. Whereas most wounds are closed in the operating room utilizing the interrupted wire technique and local or general anesthesia, some may be very amenable to tape closure. This technique can be initiated 4-6 days post debridement. Approximation of the skin edges is accomplished with micropore paper tape or wide "butterflies" applied in overlapping diagonal "basket weave"

fashion after the skin has been **degreased** with acetone, and tincture of benzoin has been applied and allowed to dry thoroughly. Edges of the wound may not come completely together with the first tape application. This is not a problem, as they will come progressively closer together with each reapplication of tape, done at 48 hour intervals. Tape closure offers some advantages over suture closure. Even compression of wound edges decreases skin edema, and the problem of cutting needles causing additional tissue damage is avoided. The wound edges are very vascular and needle passage can cause hematomas. Since tape closure is, in reality, a gradual "encouragement" of the skin toward closure rather than a total closure from the beginning, a great margin for error is added and the potential complication of wound breakdown, sometimes seen after suture closure, is almost completely avoided. No anesthesia is needed for this procedure and it can be performed by supervised ward nursing personnel.

It should be recognized that even though the surgeon diligently attempts to excise all devitalized tissue, the dynamics of wound physiology and the imperfections of one's ability to absolutely identify nonviable tissue are such that some devitalized muscle may be left behind or evolve over time in the wound. In the appropriately drained wound, this minimal amount of devitalized tissue will be absorbed or extruded. A small percentage of these wounds will require a second debridement prior to delayed primary closure. At worst, in the absence of adequate drainage, an abscess that requires subsequent drainage may develop. In this situation, antibiotics localize or isolate the deleterious effects of the injury to the site of injury, thereby precluding systemic, **life-threatening** sepsis.

TREATMENT PRIORITIES

Whereas all of the foregoing is felt to represent optimum management of war wounds, battlefields of the future may present medical officers with constraints beyond their control that preclude optimum casualty management. The lack of air superiority may deny aeromedical evacuation from forward areas. Tactical encirclement or weather may compel the forward maneuver element to hold its wounded. Battalion surgeons or physician's assistants may **find** themselves in a position where they are denied the option of moving casualties to definitive care facilities.

Medical personnel or equipment shortfalls may be the limiting factor. A resource-workload mismatch may result from a casualty generation rate that overwhelms medical capabilities. In situations such as these, the battalion surgeon and the medical treatment facility chief surgeon must be prepared to limit treatment in consonance with their capabilities and certain treatment priorities.

1) The forward medical officer should observe the general principles of resuscitation to the extent possible. The inability to surgically control high-grade hemorrhage may necessitate the prolonged use of tourniquets.

2) The early institution of systemic antibiotics is of prime importance, especially when war wounds cannot be promptly treated surgically. Tetanus toxoid and morphine analgesia are given.

3) If any surgical and anesthetic capability exists, operative treatment of wounds is usually limited to local anesthesia and wound incision to improve drainage. Under these circumstances, if wound incision is elected in the absence of blood transfusion capability, care should be exercised to avoid hemorrhage.

4) It is possible that even the larger definitive care facilities may find themselves overwhelmed by casualties or understaffed due to combat losses of their personnel. The area medical regulating officer may not be able to divert casualty excesses to other facilities. Under circumstances such as these, appropriate care may have to be limited to wound incision and antibiotics.

5) Simple non-occlusive dressings should be utilized. These dressings should allow, to the extent possible, egress of drainage from the wound.

CHAPTER XVII

Crush Injury

GENERAL

The "Crush Syndrome," or traumatic rhabdomyolysis, is a syndrome resulting from skeletal muscle injury, and the resultant release of muscle cell contents into the general circulation. This syndrome was first described in World War II air raid victims who had been trapped under fallen masonry. During peacetime, the syndrome may be seen in association with natural disasters such as earthquakes and mine cave-ins, or occasionally with vehicular disaster. Present-day terrorist activities utilizing high explosives and military operations in urbanized terrain represent current causes of the syndrome. Any individual who has been crushed beneath debris or run over, or whose limbs have been compressed for any reason for an hour or more, is at risk of developing the crush syndrome.

The collapse of a building due to an explosion causes immediate death among the majority of the victims due to the blast effect, the direct effects of the falling debris, the fire, or compression by the rubble. Immediate death is mainly caused by severe damage to vital organs. The survivors whose extremities are pinned under heavy rubble, thereby trapping them, are the ones at risk of developing the syndrome.

PATHOGENESIS

Sustained compression of a limb impedes perfusion, which results in hypoxia progressing to anoxia, muscle injury, and increased capillary permeability. The crush syndrome is a **reperfusion** injury. When the extremity is extricated from the compressing rubble, the damaged muscle liberates muscle pigment, potassium, creatinine, lactic acid, and other intracellular substances into the general circulation. The trapped victim may also be suffering from other severe injuries that contribute to or

of themselves result in shock. After release from compression, the extravasation of plasma results in swelling of the affected part. When this happens, oligemic shock is precipitated or aggravated. Untreated oligemic shock contributes to acute renal insufficiency. Liberated myoglobin, which accumulates in the renal tubules, also contributes to the development of renal failure. Liberated phosphate and uric acid aggravate an already developing metabolic acidosis. Hyperkalemia can result in sudden cardiac arrest and death. Coagulopathies not uncommonly develop. This combination of hypovolemic shock coupled with myoglobinuric acute renal failure carries a grave prognosis.

CLINICAL CONSIDERATIONS

A clear history of crush injury is not always available in wartime, and the syndrome sometimes develops insidiously in patients who appear well when they first present. Crush injuries of the trunk and buttocks can be overlooked if a complete physical examination is not performed.

Although the compressed region may appear normal when it is released from pressure, paralysis caused by the compression is sometimes present. Erythema may appear at the margin of the affected area early after release, and the adjacent skin may blister. These signs are sometimes the first evidence of damage.

Shortly after release from compression, swelling caused by extravasation of plasma appears in the part. The loss of plasma initiates or aggravates oligemic shock, and the patient's condition rapidly deteriorates. The blood pressure, which was at first maintained by vasoconstriction, falls rapidly as plasma loss continues. The damaged part, which is usually a limb, becomes swollen, tense, and hard. If it is incised, serous fluid oozes from it. The distal pulses tend to disappear. When the fascia is opened, swollen or friable muscle, which in the later stages is very pallid, bulges out. Later symptoms and signs may include anorexia, hiccups, dryness of the tongue, and drowsiness or mental disturbances as the blood urea and blood pressure mount.

In favorable cases, diuresis ensues 6-8 days after injury and the patient improves clinically, although renal dysfunction may persist for months. In less favorable cases, death may occur promptly from shock or from pulmonary edema, aggravated by the unwise forcing of fluids in the presence of renal shutdown.

Later death may be attributable to cardiac arrest caused by the hyperkalemia of uremia. In untreated cases, renal insufficiency almost always occurs within a few hours of release of compression.

Laboratory findings reveal an elevated hematocrit reflecting the state of hemoconcentration. Serum potassium and uric acid levels are elevated. The blood urea nitrogen levels are unchanged. Free myoglobin may be detected. The serum creatinine phosphokinase (CPK) is markedly elevated to at least five times normal. The first urine specimen, because it was collected in the bladder before injury, may be normal. Later, urine becomes dark due to the presence of myoglobin. It will have an acid pH.

LOCAL MANAGEMENT

The early splinting of major soft-tissue injuries and fractures is urgently important in crush injuries to minimize hypotension. To reduce tissue metabolism, the limb is kept cool by exposure to air. Unnecessary dressings and unnecessary movements of the limb are hazardous, as they cause the release of deleterious substances, particularly potassium in potentially lethal amounts, into the general circulation.

A tense and swollen limb should be decompressed immediately by liberal incision of the fascia. This measure is particularly urgent when the pressure of extravasated fluid impairs circulation. An early amputation is indicated when the limb is so severely crushed that it is obvious that function cannot be restored or when it is the only emergency procedure that permits extrication of the victim from under unmovable rubble. Debrided wounds and fasciotomy incisions should not be closed primarily.

GENERAL MANAGEMENT

Intravenous therapy should be initiated immediately after extrication or even, when possible, while the casualty is still trapped. Glucose-saline is the solution of choice; however, Ringer's solution may be used. The early objective is to achieve a constant diuresis of at least 300 cc's per hour with a urine pH of greater than 6.5. An indwelling urinary catheter is inserted. A central venous or pulmonary artery wedge pressure catheter should be utilized to guide fluid infusion and reliably monitor central pressures.

1. In the presence of an appropriate urinary response,

crystalloid solution is administered at the rate of 500 cc/hour. Bicarbonate, 445 **mEq**, is added to the crystalloid solution every other hour.

2. Urine volume and **pH** are monitored hourly.

3. Serum electrolytes, osmolality, and arterial blood gasses are evaluated at six hour intervals.

If the urinary volume is less than 300 cc per hour, **mannitol (1.0 g per kilogram body weight)** should be given intravenously. If the arterial **pH** reaches 7.45 or the urine **pH** is below 6.5, 250 mg acetazolamide should be given intravenously. This therapy should continue until myoglobin disappears from the urine. It usually takes about 60 hours to achieve this goal.

The earlier one starts intravenous therapy, the better the chance of preventing acute renal failure. When fluid therapy is delayed for six hours following extrication, acute renal failure is almost assured. If the desired urinary output cannot be achieved, the use of diuretics, preferably **furosemide**, should be considered. The majority of crush injury victims who do not receive intravenous therapy early enough and who do not respond to enforced alkaline diuresis go on to develop renal failure and the requirement for hemodialysis. If renal failure develops, prompt reduction in fluid administration is indicated.

Infection, which contributes to the development of acute renal failure, should be prevented by all possible means. Wide-spectrum antibiotics, including agents which are effective against anaerobic microorganisms, are indicated. Tetanus toxoid should be given according to the casualty's state of immunization.

The clinical features of crush syndrome may not become evident until just before the patient is to be evacuated on the basis of his other injuries. If renal insufficiency seems to be developing, the patient should be evacuated, as soon as the other injuries permit, to a medical facility that is capable of monitoring and treating the condition with renal dialysis.

Vascular Injuries

In recent wars, vascular injuries of the extremities have only comprised about 1-2% of all major injuries seen in living casualties. However, major vascular injuries are always life threatening and may result in significant morbidity among survivors. Advances in peripheral vascular surgery over the last thirty years have made it possible to repair major arterial and venous injuries not only in the civilian trauma setting but also in the combat zone hospital. Dramatic results following vascular repair can be expected if proper surgical facilities and experienced personnel are available. On the other hand, the performance of major vascular operations requires a significant commitment of time and resources. When surgical facilities are inadequate or overrun by large numbers of casualties, the performance of major vascular procedures is inappropriate. Under such unfortunate conditions, amputation rather than vascular repair may be more appropriate. Under these circumstances, experience and mature **judgement** are required to make the proper decision for each patient.

TABLE 10.—*Arterial wounds and associated injuries, Vietnam, 1965-1970*

Location	Total #	Nerve		Vein		Bone	
		#	%	#	%	#	%
Axillary	59	54	91.5	20	33.8	16	27.1
Brachial	283	202	71.3	54	19.0	96	33.9
Iliac	26	3	11.5	11	42.3	2	7.6
Femoral, common	46	7	15.2	18	39.1	9	19.2
Femoral, superficial	305	61	20.0	139	45.5	72	23.6
Popliteal	217	81	37.3	113	52.0	87	40.0
Total	936	408	43.5	355	37.9	282	30.1

Major vascular injuries almost always require prompt surgical intervention if the tissues supplied are to be salvaged. Diagnosis and preliminary management should begin in the field, and these patients should be evacuated promptly to a definitive treatment facility. Operational conditions may have a profound influence on the ultimate outcome of vascular injuries. During the Vietnam conflict, for instance, helicopter evacuation allowed many who might have otherwise expired to reach the hospital alive. Whether or not similar circumstances will exist in future conflicts remains to be seen.

GENERAL PRINCIPLES

As in the civilian sector, the majority of combat-incurred vascular injuries that are amenable to surgical repair involve peripheral vessels. The majority of those with central vascular injuries or injuries of the thoracic or abdominal aorta usually do not survive to reach a surgical facility capable of dealing with these injuries. The penetrating and perforating vascular wounds of the battlefield, as opposed to those of the civil sector, are more likely to have been caused by high-velocity projectiles. High-velocity missiles more often cause secondary damage to adjacent tissues as a result of temporary cavitation. Secondary fragments resulting from either fragmentation of the projectile or from fragmentation of bone will cause additional damage. Temporary cavitation can result in thrombosis of an artery even though the missile does not actually strike the artery. This results from intimal disruption, subintimal dissection of blood, and intimal prolapse and subsequent thrombosis.

The use of various fragmentation devices in military operations creates the potential for multiple vascular injuries (as well as other major nonvascular wounds) in the same individual. The multiplicity of wounds must be taken into account in the overall management of the patient.

Although the surgical repair of vascular injuries is usually urgent, it must not be done precipitously. Every surgeon confronted with a casualty with obvious major vascular injury must also determine what other injuries are present and formulate the best overall management plan. Priority of care must be established for each injury. The ability of the patient to tolerate the

additional operative time required for vascular repair must also be considered. Finally, adequate resuscitation usually must be accomplished before the reparative vascular procedure is attempted. In some cases, the control of hemorrhage will be part of the process of resuscitation. Failure to observe these basic precautions may result in loss of life as a result of overzealous attempts to salvage a limb.

DIAGNOSIS

Injuries to blood vessels consist of several types. Among these are lacerations, transections, avulsions, and contusions. The latter may or may not be associated with intimal injury. All can result in spasm, thrombosis, expanding hematoma, and distal thrombus embolization. Full-thickness injuries may result in false aneurysm, arteriovenous fistula, and life-threatening hemorrhage. Neurological symptoms may develop secondary to ischemia, associated nerve injury, neural compression by expanding hematoma, or a compartment syndrome.

Diagnosis of vascular injury is sometimes difficult. This is especially true when a missile track is near a major vessel but distal pulses are still intact. Classically, a cold, pulseless extremity results from an arterial injury. Similar physical findings can occasionally be the result of environmental exposure, shock, arterial spasm, or crush injury. At times, an accurate diagnosis is not possible until exploration is undertaken. In most instances, however, the following signs and symptoms (commonly referred to as the 5 Ps) may be taken as presumptive evidence of arterial injury: pain, pallor, pulselessness, paresthesia, and paralysis. Additional findings may include contracture, mottling, and cyanosis. Anesthesia or external hemorrhage may or may not be present. In some cases, the injured limb may be clearly larger than the uninjured limb due to the presence of a large subfascial hematoma.

For the most part, the surgeon will have to rely solely on clinical skills in diagnosing and evaluating postoperative patency of arterial repairs. However, during the Vietnam conflict, it was shown that the Doppler instrument could be used effectively in the combat setting. Nowadays, sturdy, lightweight, and inexpensive instruments are widely available, and will in all likelihood be available in combat zone hospitals.

SURGICAL TIMING

The management objective of arterial injuries is restoration of arterial flow at the earliest possible moment. As the time lag from injury to repair increases, so increases the failure rate of arterial repair. While the best results are obtained when blood flow is reestablished within six hours of injury, it remains impossible to define the precise time beyond which successful repair can be expected. Thus, there is no inflexible time limit beyond which arterial repair is absolutely contraindicated.

When occlusion of a major artery occurs as a result of trauma, limb viability depends on collateral circulation. Whether or not operation can be delayed in such cases is dependent upon the adequacy of collateral blood flow. Irreversible muscle damage may occur within a few hours if collateral circulation is inadequate. On the other hand, limb survival may occur without arterial repair in some cases solely on the basis of collateral blood flow. In such cases, false aneurysms and arteriovenous fistulae may present as delayed manifestations of the acute injury. Since it is usually not possible to determine the irreversibility of ischemic damage by clinical means, repair of major blood vessel injuries should be performed even in questionable cases if support is available. Although the entire limb might not be salvaged, a more distal level of amputation may result.

PRINCIPLES OF TREATMENT

Control of Hemorrhage

In most instances, hemorrhage from peripheral arterial and venous injuries can be controlled by a well-placed compression bandage. If a tourniquet must be placed as a lifesaving measure, it should be as distal as possible on the extremity and it should be tight enough to control both arterial and venous hemorrhage. Once applied, for control of arterial hemorrhage, the tourniquet should be left in place until removed by a medical officer, usually at the hospital in an operating room.

At the time of operation, direct pressure over the traumatized artery both proximally and distally by an assistant usually

provides adequate temporary control of hemorrhage until direct control can be obtained with vascular clamps. An anatomical approach to provide adequate exposure to the injured vessels should be used regardless of the location of the wound. In large wounds, the ends of the artery may already be visible. In such cases, the severed ends can be controlled directly with clamps. When the vessel ends are not exposed, proximal and distal control is usually obtained through normal tissue planes by application of umbilical tapes, silastic loops, or vascular clamps. Intraluminal control using balloon-tipped catheters is also effective and is particularly useful in the repair of false aneurysms. These devices, originally developed and field tested during the Korean War, are available in combat zone hospitals.

Noncrushing vascular clamps should be used to control hemorrhage. If crushing clamps were placed under emergency conditions, they should be replaced with noncrushing clamps, and the crushed portion of artery should be resected prior to definitive repair. If noncrushing clamps are not available, atraumatic control can be achieved with double-looped cotton or silastic tourniquets or with Rummell tourniquets.

If an extremity arterial injury is distal enough to permit the use of a pneumatic tourniquet, a great deal of time and blood loss can be saved during exposure and control of the injured vessel. The tourniquet should not be inflated until it is actually needed, and it should be deflated as soon as the injured vessel is under control to allow flow through collaterals.

Debridement and Evaluation of Patency

After gaining control of the injured artery, rapid wound debridement is accomplished in the standard fashion. Excision of devitalized tissue should be complete, including any damaged artery. Debridement of the artery itself should be as conservative as possible. Only grossly injured artery should be excised. Although microscopic changes have been found in the normal-appearing artery adjacent to the obviously traumatized segment, there is no evidence that resection of normal-appearing artery on either side of an injured segment is necessary.

Distal arterial patency may be evaluated before repair by careful passage of a balloon tipped catheter. One cannot be certain of

distal arterial patency based on the presence of or the rate of back bleeding, as back bleeding simply indicates patency to the level of the first major collateral. Only operative arteriography or reestablishment of distal pulses after repair can be considered proof of distal arterial patency.

The possibility of additional arterial injuries, either close to or at some distance from the recognized injury, should be considered and demonstrated either by intraoperative arteriography, if practical, or by direct exploration. Failure to repair a second arterial injury usually leads to a poor result regardless of the adequacy of repair of the initially recognized injury.

Conservative Management

Some arterial injuries may be treated in the acute stage without operation. When an artery is severed, there may be little or no external hemorrhage because of vessel retraction and arterial compression by an expanding hematoma within the associated musculofascial compartment. As the compartmental pressure approaches that in the damaged artery, hemorrhage stops and a stable pulsating hematoma develops. As encapsulation of the hematoma occurs, a false aneurysm forms. Some of these false aneurysms may be missed in the acute stages and will require repair when recognized later.

When both the artery and vein are injured, an acute arteriovenous fistula may result. Patients with well-established arteriovenous fistulae who present without secondary hemorrhage, and whose extremities are viable, have a low priority for operation in the combat zone. This is also true for pulsating hematomas when recognition of the arterial injury has already been delayed and viability of the limb has been preserved by collaterals.

One must use caution in electing not to operate emergently on the above-mentioned vascular injuries. When surgical capabilities are adequate, there is little justification for nonoperative management of arterial injuries. Delay of operation in hopes of development of a false aneurysm or arteriovenous fistula with concomitant adequate collateral circulation can be rationalized only when the capability to perform arterial surgery is nonexistent or marginal.

Surgical Repair

Lateral suture repair is suitable for small, clean-cut lacerations of large arteries. For larger tangential wounds, an autogenous vein patch should be used to prevent stenosis of the repair site. If damage to the affected artery is extensive or irregular, the damaged segment should be excised and continuity reestablished by end-to-end anastomosis or an interposition graft.

After the artery has been adequately debrided, noncrushing vascular clamps are applied at about one centimeter from each end of the transected vessel. At this point, it is determined if the ends can be anastomosed without tension. Undue tension must be avoided as it is likely to result in dehiscence and hemorrhage, or anastomotic narrowing and thrombosis. In any case, undue tension will doom the repair to failure. The surgeon readily develops judgment concerning the amount of tension which can be safely applied to a vascular repair. When too much tension exists, further dissection is carried out proximally and distally. A moderate amount of dissection may compensate for a defect as long as two centimeters but rarely for one longer than this. Branches of the damaged artery generally should not be sacrificed since this practice gains little length while at the same time sacrificing important potential collaterals—collaterals that could be of critical importance should the primary repair fail.

Direct anastomoses are most often performed using a running technique. A continuous suture is placed through the full thickness of the vessel wall with individual passes about 1.0 mm back apart and 1.0 mm from each cut end. In vessels the size of the radial, ulnar, or tibial arteries, an interrupted suture technique should be used. Although care should be taken to avoid pulling adventitia into the lumen as the needle passes from the outside to the inside of the vessel, it is not necessary to perform a formal excision of the adventitia, as doing so weakens the repair. To assure preciseness of coaptation, the vessel ends can be held in a constant relationship to one another by lateral stay sutures as the continuous anastomosis is performed. Synthetic monofilament vascular sutures of 5-0 or 6-0 on cardiovascular needles are most commonly used for venous and arterial repairs. Aortic injuries are more commonly repaired with 3-0 monofilament synthetic sutures. Braided arterial silk lubricated with sterile mineral oil or by passage through subcutaneous fat may be used if synthetic

suture is not available, as may braided synthetic sutures with an external plastic coating which approximates the characteristics of a monofilament suture.

During repair, the lumen of the vessel should be inspected to assure that no local thrombi are present. If present, thrombi should be removed by flushing with heparinized physiologic saline (10 units/cc).

Small leaks from the suture line are usually controlled by pressure alone. Topical hemostatic agents, such as **gelfoam**, collagen powder or topical thrombin are also useful in controlling minor suture line leaks and leaks from needle holes. Larger leaks are best managed by carefully placed figure-of-eight or mattress sutures.

Management of Associated Injuries

Unstable fractures can compromise vascular repairs. Bone length should be regained and fractures should be rapidly realigned and stabilized prior to vascular repair. Internal fixation is contraindicated, because of the risks of infection. External stabilization by skeletal traction or rapidly applied external fixation devices should be utilized. Dislocations, which result in ischemia due to distortion or compression of the associated artery, should be reduced immediately.

Concomitant nerve injuries which may occur in association with any vascular injury are more common in the upper than in the lower extremity. Repair of nerve injuries is generally not recommended in the combat zone. If nerve ends can be found expeditiously, they should be tagged with a nonresorbable suture for delayed elective repair.

Injuries to major veins should be repaired whenever possible. This is particularly true of injuries of the iliac, common femoral, superficial femoral, and popliteal veins. Occlusion of these veins frequently results in significant edema and late sequelae similar to the post-phlebotic syndrome. In some instances, simple closure techniques such as lateral repair may be possible. In others, more complex repairs using panel or spiral vein grafts may be needed. In such instances, the greater saphenous vein from the opposite, rather than the ipsilateral, extremity should be used. Preservation of the ipsilateral greater saphenous vein preserves an important

source of venous outflow, should the venous repair fail.

Choice **of** Conduit

When major arteries or veins require patching or replacement, the surgeon must decide which patch material or conduit to utilize. Conventional wisdom is that the greater saphenous vein is the material of choice. It should be harvested from the uninjured extremity whenever possible to avoid compromising venous outflow from the injured extremity and wound healing problems should an arterial repair fail and result in marginal ischemia. When the greater saphenous vein is not available, the lesser saphenous vein is the next best choice, as its histology is similar to that of the greater saphenous vein. Upper extremity veins are another available source of patch material or conduit, but have thinner walls and are thus more prone to degeneration and aneurysm formation. Neck veins should **not** be used because they are too thin walled to withstand arterial pressure. In the trauma setting, autogenous arteries and synthetic conduits should be used only under extreme circumstances, when no other vascular substitute is available. Synthetic conduits of all types are prone to infection. In the rare event that a synthetic conduit is needed, **poly-tetrafluoroethylene (PTFE)** is preferable to Dacron, as it appears to have a better chance of resisting and withstanding infection.

POSTOPERATIVE CARE

After arterial repair, the injured limb should be kept at or slightly above the level of the heart. If the extremity has been flexed, gradual extension over a period of several days is encouraged to avoid development of a contracture. Equinus deformity of the ankle is prevented by assuring that the ankle is splinted in a neutral position. Active muscle exercises are begun in the early postoperative period. As soon as other injuries permit, ambulation is encouraged and progressively increased.

When arterial continuity has been restored in situations where there is questionable viability of muscle tissue, the patient must be observed closely for (1) a decrease in urinary output, which is evidence of acute renal insufficiency; (2) increasing temperature

and pulse rate as evidence of wound infection; and (3) increasing pain, confusion, fever, and tachycardia. These latter signs of toxicity may be evidence of clostridial myositis. Myoglobinuria may result from muscle necrosis. Development of any of the above are indications for debridement of necrotic muscle or for early amputation of a clearly nonviable extremity. If the vascular repair fails, but none of these complications develops, amputation of the nonviable extremity can be deferred until a clear line of demarcation is established.

If fasciotomies were not performed at the time of arterial repair, the patient must be carefully observed for development of a compartment syndrome. Fasciotomy should be seriously considered at the time of arterial repair when there has been a concomitant major venous injury, when there has been a delay of greater than six hours between arterial injury and repair, when there has been an associated crush injury or muscle maceration, and when significant edema is already present at the time of operation. Therapeutic fasciotomies should be performed at the first clinical evidence of an increase in compartment pressures as manifested by loss of previously present pulses, or the development of paresthesias or anesthesia in the distribution of the major nerves supplying the affected part. In the upper extremity, additional clinical signs suggesting the need for fasciotomy include pain on passive motion of the fingers and thumb, and spasm of the wrist and finger flexors leading to a persistent flexion attitude of these structures. In the lower extremity, the first nerve to suffer is the deep peroneal, as manifested by pain on passive motion of the ankle and great toe and decreased sensation in the dorsal web space between the great toe and the second toe.

If compartment pressures are measured, a pressure between 30-40 mm Hg should increase one's vigilance and should lead to fasciotomy if signs and symptoms develop. A compartment pressure greater than 40 mm Hg represents a recognized indication for fasciotomy. In the lower leg, adequate decompression of all four compartments can be obtained through two incisions. One posteromedially-placed incision is used to open the superficial and deep posterior compartments. A second incision placed anterolaterally is used to open the anterior and lateral compartments. The vertical skin incisions should measure 10-12 cm in length and should be left open for delayed primary closure or skin grafting, if necessary. The fascia can be opened all the way to the

ankle using either a fasciotome or scissors.

Fasciotomy of the forearm and hand requires four incisions. Two are placed vertically on the dorsum of the hand between the second and third and the fourth and fifth **metacarpals**, respectively. A third incision is placed vertically on the dorsum of the forearm. The final incision is used to decompress the flexor compartment of the forearm and the palm of the hand. This incision is a lazy-S which starts on the proximal ulnar forearm, curves across to the radial flexor forearm, returns to the ulnar forearm, then extends to the mid-palm just ulnar to the thenar crease.

ADJUNCTIVE THERAPY

Intravenous broad spectrum antibiotic therapy should be initiated as soon as possible after injury. This should be continued throughout the operation and for roughly 24 hours thereafter, assuming there is no continued source of contamination. In most instances, a cephalosporin provides effective prophylaxis.

Anticoagulation of the distal arterial tree is acceptable during operation, but one must be aware that, because of collateral flow, locally injected heparin ultimately becomes systemic. For this reason, relatively small doses of heparin (1500-3000 units at a concentration of 100 units per cc of physiologic saline) are used for anticoagulation of a lower extremity. Systemic anticoagulation is usually not advisable because of the presence of associated injuries. There is rarely, if ever, an indication for postoperative **an-**ticoagulation. Adjunctive agents, such as low molecular weight dextran, may be used and may be of value particularly after small artery repairs; however, dextran must be used with caution to prevent volume overload. In most instances, vascular repairs will be successful if the tissues are adequate, the repair is done well, and the hemodynamic and volume status of the patient are kept within normal limits postoperatively.

Although preoperative arteriograms are rarely available in the combat setting, single-shot hand-injected intraoperative arteriograms can be easily obtained and are helpful to rule out additional arterial injuries, distal thrombosis, and inadequacy of the repair. Injection of full-strength contrast (Radio-Conray 60) through a 19 gauge needle usually results in an excellent study.

Fifteen to 20 cc is usually all 'that is needed. The film should be exposed while the contrast material is still being injected. At times, run-off may be so rapid that the contrast is washed out by the time the film is exposed. Should this occur, a second injection with in-flow occlusion will usually provide adequate visualization. Sympathetic blocks and sympathectomy are of no value in the management of acute arterial injuries. Sympathectomy, as a delayed procedure, may occasionally be helpful to the patient who has had a suboptimal result from arterial repair.

COMPLICATIONS

The most serious of the common complications after repair of arterial injuries are infection and hemorrhage. Infection of a wound harboring an arterial repair frequently results in disruption of the suture line or degeneration of the conduit used for revascularization. Either may result in life-threatening hemorrhage. Secondary repair should not be attempted within the infected wound site. Occasionally it may be possible to bypass the infected wound and revascularize the extremity using an extra-anatomic route. In other instances, this will not be possible, and proximal and distal arterial ligation with removal of the infected conduit will be required. This will, of necessity, result in a high percentage of amputations.

Thrombosis at or distal to the vascular repair is another potential complication. It may be necessary to perform a second operation in the early postoperative period if thrombosis occurs and viability of the limb is threatened. However, if limb viability is maintained by collaterals, additional operations in the combat zone should be avoided, as repeated operations under field conditions are followed by a higher incidence of infection which jeopardizes life as well as limb. If chronic arterial insufficiency develops, secondary vascular operations should be performed electively at a higher echelon of care.

A limb that is profoundly ischemic after arterial injury may develop ischemic contracture. This complication can be prevented if perfusion is restored within a reasonable period of time. When circulation is restored, muscle groups may swell, necessitating fasciotomies to prevent compartment syndrome and small vessel occlusion, which can cause myonecrosis even in the presence of

a successful arterial repair. These changes are most prone to occur in the flexor compartment of the forearm and in the anterior compartment of the leg. Under some circumstances, prophylactic fasciotomies, as discussed earlier, may be indicated to prevent delayed development of compartment syndrome.

RESULTS

Prior to the Korean conflict, major vascular injuries were routinely treated by arterial ligation. This resulted in a 50% amputation rate. Combat zone arterial repairs, rather than routine amputation, were **first** accomplished in Korea. This practice was continued in Vietnam, where thousands of arterial repairs were performed. Amputation rates after acute arterial repair were lowered to 13.7%. Popliteal arterial injury continues to be associated with a higher amputation rate. Rapid evacuation and resuscitation of the wounded in future conflicts should continue to result in high rates of salvage of both life and limb.

Wounds and Injuries of Bones and Joints

The frequency of extremity injuries in combat invariably generates significant numbers of bone and joint injuries. These injuries may be closed (simple) but are usually open (compound). Closed injuries are treated as they might be under other conditions, with the exception that elective surgical procedures should not be performed in forward medical facilities. The management of the open injury begins exactly as for open soft-tissue injuries (Chapter XVI). The immediate objectives in the treatment of these injuries are the preservation of neurovascular function and the prevention of infection. Complete wound healing and return to full function constitute the long-term goals. Staged wound management consisting of thorough debridement and delayed wound closure will convert an open injury to a closed injury in a high percentage of cases. Historically, failure to adhere to this basic principle of management has consistently yielded an unacceptably high incidence of infection and has frequently resulted in catastrophic functional loss.

GENERAL PRINCIPLES

The forward surgeon should manage open injuries of bones and joints according to the following general principles:

1. Evaluation. One must initially determine the extent of the wound and of the structures involved. In high-velocity missile wounds, tissues and structures at some distance from the actual wound tract may be damaged and require debridement.
2. Prophylaxis. Parenteral antibiotic treatment and tetanus prophylaxis should be initiated at the earliest opportunity. In

general, broad spectrum antibiotic coverage for both Gram-negative and Gram-positive organisms is recommended. Since all open war wounds are contaminated and present a risk of developing tetanus, all of these individuals should receive a 0.5 cc IM tetanus toxoid booster injection. Antibiotics and tetanus coverage should never be construed as a substitute for adequate wound cleansing and debridement.

3. **Debridement.** Generous incisions should be the rule. Such incisions permit better exploration of the wound, facilitate removal of foreign material (clothing, soil, vegetation, accessible metal fragments), and allow more complete excision of all devitalized tissue. In general, small, detached bone-chip fragments should be removed, but major in situ fragments with significant soft tissue attachments should be retained. Copious irrigation of the wound, with pulsatile lavage if possible, is mandatory. Properly performed debridement provides the basis for prevention of infection and the success of all future treatments, including reconstructive surgical procedures. Definitive surgery, primary closure of wounds, relaxing skin incisions, and nerve and tendon repair have no place at this stage of treatment.

4. **Arthrotomy.** Penetrating joint wounds require arthrotomy irrigation, thorough surgical exploration, and debridement.

5. **Vascular repair and fasciotomy.** These are the only appropriate definitive procedures performed at the time of initial wound surgery. Vascular injuries should be addressed through "wounds of election" and fasciotomies should be routinely performed following vascular repairs. If possible, an attempt should be made to cover the vascular repair with viable soft tissue; however, the wound should be left open.

6. **Leave wound open.** Perhaps the most important principle after debridement of war wounds is to leave the wound open. Bleeding points are controlled, but otherwise no attempt at wound closure is made, and drains are usually not necessary.

7. **Nonocclusive dressing and immobilization.** The wound is covered with a sterile, bulky, nonocclusive dressing and the extremity appropriately immobilized by plaster splints or a plaster

cast which is immediately **bivalved**. In some cases, external skeletal fixation may be utilized.

8. Documentation. It is important to document in the medical record all operative findings, particularly vascular, neural, tendon, or muscle damage, in addition to the more obvious skeletal injury. This information is vital to subsequent care providers as the patient progresses through the evacuation chain. If a plaster dressing is used, this information can also be briefly documented with a marking pen on the plaster itself.

Adherence to these general principles at all treatment levels will substantially enhance the likelihood of functional recovery and minimal morbidity.

MANAGEMENT BY FIELD MEDICAL PERSONNEL

The combat medic's main objective in the initial management of the casualty is to do no further harm and to evacuate the patient rapidly to a definitive treatment center. Wounds are covered with sterile dressings and hemorrhage is controlled by local compression. Rarely, a tourniquet may be necessary but normally should be avoided. If used, the tourniquet should not be released before arrival at a definitive surgical facility. Extremities with fractures should be gently aligned and splinted; no attempt should be made to reduce these injuries. Fluid replacement should be initiated.

MANAGEMENT AT THE FORWARD HOSPITAL

Following resuscitation, antibiotics should be started immediately according to the principles outlined in Chapter XI.

At operation, a properly applied tourniquet is a definite aid in locating and controlling sites of major hemorrhage. Attention to accepted tourniquet usage principles is mandatory. In almost every case, the tourniquet, if used, should be released after two hours. It is also an absolute necessity that any tourniquet used during the procedure be released at the conclusion of the procedure prior to dressing to ensure appropriate hemostasis. Wound debridement should be carried out through generous incisions generally in the long axis of the extremity, avoiding the crossing of **flexion** creases at right angles.

Incisions should be planned such that the option to extend them is maintained. One should attempt to place the incision such that later reconstructive surgery is not compromised. The full extent of the wound including the deep fascia, should be widely exposed to facilitate the complete removal of foreign material, devitalized muscle, and other nonviable tissue (Chapter XVI). Small fragments of bone without soft-tissue attachment should be discarded, but larger fragments, particularly those contributing to length and circumferential integrity and those with significant soft tissue attachments, should be retained. Large, completely detached fragments should be cleaned thoroughly and replaced as near to their anatomical positions as possible. The wound should be copiously irrigated with pulsatile lavage containing an antibiotic solution whenever possible. Irrigation is an extremely important aspect of wound debridement, and with major injuries should optimally consist of approximately 10 liters of solution. Vascular repairs are accomplished as indicated in the acute phase, but nerve and tendon repairs should not be performed at this stage of treatment of battlefield casualties.

As has been said, the wound must not be closed. No attempt should be made to effect wound coverage. Relaxing incisions, pedicle flaps, or any other definitive plastic type of wound approximation techniques are contraindicated at this time.

The wound should be dressed with a single layer of fine-mesh gauze followed by bulky fluffed gauze, then wrapped. Packing of the wound, which impedes drainage and capillary flow, should be avoided (Chapter XVI).

FRACTURES

In the early stages of treatment, certain principles of war wound management should be adhered to:

1. The neurovascular status of all injured extremities must be accurately established and recorded.
 2. All open fractures require open debridement and irrigation.
 3. The fractures should be reduced and aligned as accurately as possible and initially splinted in some fashion. As previously stated, the neurovascular status of the extremity must be established and care must be taken not to compromise the vascular status of the extremity. If fracture reduction results in circulatory
-

insufficiency, the fracture **must** be repositioned and/or the cause of circulatory insufficiency delineated. Biplanar radiographs are desirable to optimally treat any fracture. It should be kept in mind that the primary objective in management of extremity wounds is to optimize the situation such that early wound healing can be obtained, infection prevented, and function restored.

4. Internal fixation of fractures resulting from war wounds is generally contraindicated in the initial stage of wound management. While there are some exceptions, this should be considered a generally universal principle. Fractures in extremities where vascular repairs have been performed are no exception; past combat experience has demonstrated that traction or other forms of external immobilization can be utilized with vascular repairs. The addition of internal fixation material to a wound containing a vascular repair results in an unacceptably high risk of infection and breakdown of the vascular repair.

5. Fractures can be stabilized by the use of splints, circular dressings, pins incorporated in plaster casts (Figure 25A), or external fixators (Figure 25B). An external **fixator** should only be applied only by a surgeon familiar with its indications, application, and potential complications. The fixator can be extremely useful in the management of large open wounds in which there has been considerable bone or soft tissue loss or where vascular repair is to be performed. The advantages in these types of situations are rapid application, ability to maintain length and position, the ease of access to the wound for dressing changes and repeat wound debridement, and control of pain because of the stability provided. The rigid fixation attained frees adjacent joints that would be immobilized in plaster casts and eliminates the additional weight of the cast, allowing crutch ambulation or transportation in a sitting position in many patients who would otherwise be **litter**-bound. Additional uses are the control of hemorrhage in displaced pelvic fractures, and the care and mobilization of patients with humeral, pelvic or femoral fractures with associated chest or abdominal wounds. **Sufficient** rigidity can be obtained in most long bone fractures with the use of a single frame configuration, consisting of one longitudinal bar attached by two or three pins distal and proximal to the fracture, to allow early care and transportation. The use of half-pins, which pass through the soft tissues on one side to engage the bone but do not penetrate the soft tissues on the opposite side, minimize the risk to adjacent nerves, vessels,

and muscles. Predrilling the **b**one with a drill bit and daily local pin care minimize the complications of pin loosening and pin tract infection.

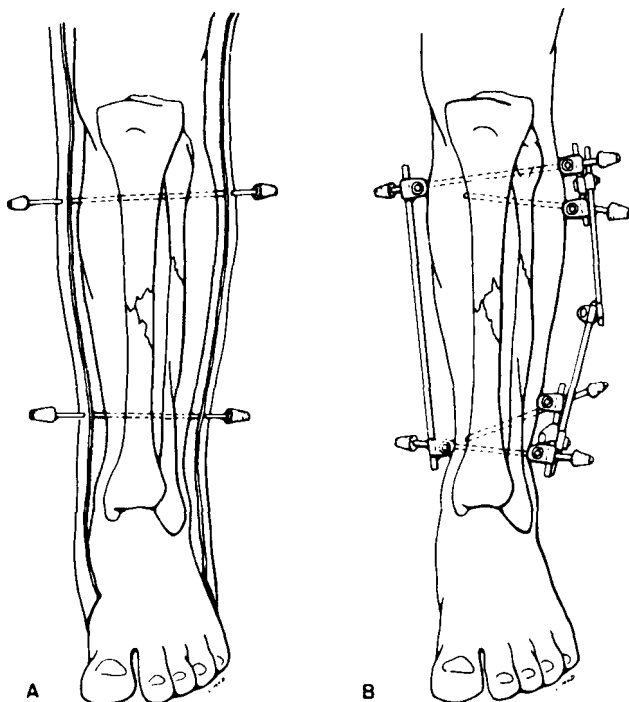


FIGURE 25.—External fixation of fractures. A. Pin and plaster technique. Cast must be bivalved. B. External fixator.

6. A circular plaster dressing (cast) is applied for immobilization of the joints above and below a fracture. Once applied it must be immediately bivalved to the skin. A monovalved cast has no place in the early treatment of a combat casualty. Bivalving the cast for transportation and evacuation is mandatory. Plaster casts should be marked with identifying information pertinent to the underlying injury and the date of cast application for use during transit and by receiving personnel. In general, plaster splinting is inadequate for anything other than temporary field immobilization. If a **spica** cast is constructed, one should avoid making the cast much wider than a standard litter; this will facilitate movement during medical evacuation.

7. When skeletal traction is employed, Steinmann pins are

preferable to **Kirschner** wires. They can be easily incorporated into the plaster cast for evacuation and are less likely to bend. In general, the larger diameter pins should be utilized to prevent loosening and pin traction infection. Incorporation of traction bows into the cast is unnecessary.

8. Fractures of the humerus or injuries to the shoulder girdle, with or without brachial artery repairs, are best transported in a Velpeau dressing with the extremity strapped across the chest; a "sling and swath" can be substituted if necessary (Figure 26).

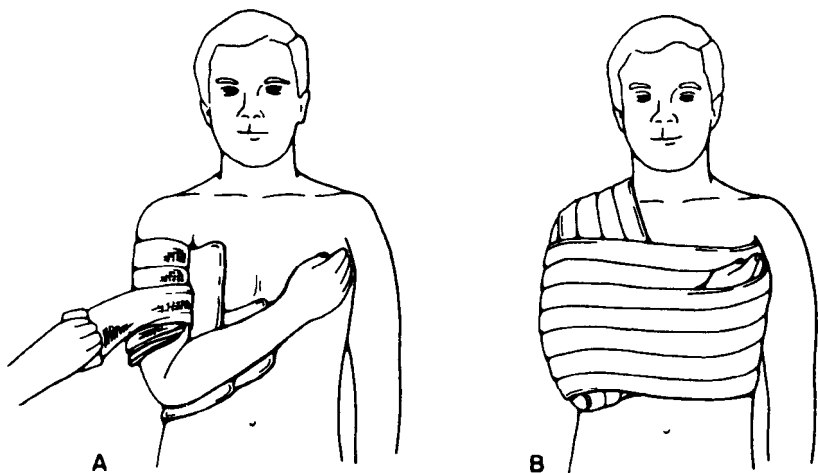


FIGURE 26.—Immobilization of upper extremity. A. Position of arm and forearm. B. Immobilization effected by binding arm to chest.

9. Elevation of an injured extremity facilitates venous return and minimizes swelling. Ice, when available, can also be applied in the early injury phase to help control swelling and make the patient more comfortable. The neurovascular status of the extremity should be carefully monitored after treatment, and in injuries of both the forearm and the leg the surgeon must be constantly alert to insure early recognition of compartment syndrome.

10. When plaster casts or splints are utilized, particularly in the patient with impaired sensation, vigilance must be maintained to prevent skin breakdown from excessive cast pressure. Complaints of pain under the cast must not and cannot be ignored. Patients in **spica** casts should be turned at intervals to prevent

pressure sores over the sacrum and other bony prominences. Cast pressure can be minimized by the use of properly padded and applied plaster.

11. The possibility of fat embolization should be considered in all patients with long-bone fractures. This is particularly true in patients developing signs of cerebral or pulmonary dysfunction. Adequate oxygenation is fundamental in the treatment of fat embolism syndrome and frequently requires the use of mechanical ventilation and positive-end-expiratory pressures. At the present time there is no hard evidence that validates the efficacy of intravenous alcohol, heparin, or steroids in the treatment of this primarily respiratory syndrome. Treatment consists of supporting the patient's respiratory function.

12. Preferred regional splinting is as follows:

a. The shoulder joint and humerus, depending on the injury, can be splinted or immobilized in several manners. As previously noted, a sling and swath or Velveau-type of dressing is satisfactory for many injuries. A well-padded, plaster shoulder spica for more significant injuries provides better support during transportation. The shoulder spica cast is extended to include the forearm but not the wrist. An external fixator applied on the lateral aspect of the humerus with half-pins is a useful alternative to the shoulder spica or in those with associated chest wounds.

b. The elbowjoint and forearm is normally immobilized with a plaster cast, with the elbow at approximately 90° of flexion and the wrist and forearm in a neutral position. The plaster extends from the proximal palmar crease to the axilla. A sling or a collar and cuff should be used to support the cast and will increase patient's mobility and comfort.

c. If the injury is limited to the wrist itself, the plaster extends from just below the elbow to the proximal palmar crease (short arm cast). The wrist should be held in a position of approximately 30° of dorsiflexion. If the thumb is incorporated, it should be positioned such that the digits can oppose the distal thumb. The hand should be immobilized with the metacarpal-phalangeal joints flexed and the interphalangeal joints extended when possible. An unaffected digit should not be incorporated into the splint or dressing. An external fixator or pins incorporated in a short arm plaster cast are especially useful to prevent shortening in severely comminuted fractures and those with bone loss.

d. To immobilize the hip joint or a femoral fracture, a

bilateral plaster spica extending from the axilla to the toes on the affected side can be used. The knee should not be immobilized in hyperextension nor should it be immobilized beyond 10-15° of flexion. The spica extends to just proximal of the knee on the unaffected side. When the spica includes the foot, care must be taken that the normal arch of the foot is maintained and that the foot is not held either in inversion or eversion. When a cast includes the toes, plaster must be trimmed away on the dorsum of the foot to a point just proximal to the base of the toes, thereby permitting the toes to move freely and protecting them from further injury. This precaution permits periodic evaluation of the distal neurovascular status. An external fixator applied on the lateral aspect of the femur with half-pins is especially useful in open femoral fractures. In fractures of the pelvis or hip associated with abdominal or perineal injuries, a pelvic frame alone, or one attached to a femoral frame, greatly aids nursing and wound care

e. To immobilize the lower leg and ankle extend the cast from the groin to the toes. The knee is immobilized with slight flexion avoiding hyperextension or full extension. The foot is placed in neutral dorsiflexion (at a right angle to the leg). The same care is taken with respect to the foot as was described in the paragraph above. A single frame applied to the anterior tibia with half-pins allows mobilization of the ankle and knee with crutch ambulation, while maintaining length and easy wound access.

f. A plaster cast for the foot and ankle is applied from just below the knee to include the toes as previously described (with the foot in neutral). Care must be taken that excessive pressure is not placed on the peroneal nerve which courses just below the lateral aspect of the fibular head.

13. Joints not immobilized should be actively exercised on a frequent basis.

JOINT INJURIES

A penetrating wound of a joint has a high potential for infection which can often be avoided or at least minimized by appropriate surgery. In addition to the previously described techniques of wound surgery, the following specific principles are applicable to open joint injuries:

1. For all penetrating injuries of a joint, a formal arthrotomy

is required. While this sometimes can be accomplished through the actual wound itself by extending it as necessary, a separate standard arthrotomy incision may be required. The extremity should be draped in a manner that allows movement of the joint as necessary to facilitate exposure. Arthrotomy should be done as soon as possible after injury in an operating room. If applicable, the use of a tourniquet is recommended.

2. All loose bony fragments, detached or badly damaged cartilage, foreign bodies, clots, and devitalized tissue should be removed. Biplanar radiographs are desirable.

3. The joint should be thoroughly explored utilizing appropriate retractors.

4. The joint should be copiously irrigated with an antibiotic-containing solution, utilizing pulsatile lavage when possible.

5. The wound should be left open. The same principles apply to joint injuries as to open fractures with respect to wound closure. Depending on the degree of contamination, it may be possible to close the synovium leaving the capsule or soft tissue open. However, closure of the synovium is not absolutely necessary provided an occlusive dressing is applied.

6. If the synovium or capsule cannot or should not be closed because of joint contamination, the open joint should be dressed carefully with a single layer of fine-mesh gauze and followed by fluffed gauze and a wrap. Depending on the degree of damage of the articular surface, appropriate immobilization may be instituted. Early motion should be considered in those injuries where the joint surfaces are not significantly involved.

7. Penetrating wounds of the lower abdomen and pelvic area should be evaluated carefully for involvement of the hip joint. Any evidence that the hip has been penetrated requires arthrotomy, exploration, irrigation, and drainage. Frequently these procedures coincident with the abdominal operation. Posterior arthrotomy may be necessary to adequately accomplish the surgical goals; care should be taken with respect to the posterior blood supply of the femoral head.

8. Joint injuries thus treated should be dressed and immobilized as previously delineated for fractures.

COMPARTMENT SYNDROME

Compartment syndrome in the leg and forearm is a potentially devastating complication. The pathophysiology is at the microvascular level, and failure of early recognition of the syndrome can lead to severe functional loss or amputation. The surgeon must have a high index of suspicion. An open fracture does not necessarily decompress the compartments and in fact, because of the high energy associated with the injury, may increase the risk of such a syndrome. The classic findings of pain, paralysis, pulselessness, and paresthesia usually present is too late to successfully intervene. Patients with significant trauma, who have been treated and splinted but continue to have unremitting pain in the involved extremity, particularly with passive motion of the digits, should be considered to have a compartment syndrome until proven otherwise. Compartment syndromes are progressive problems that may develop insidiously, thereby requiring repetitive examinations of the extremity. Diagnosis is clinical and the treatment is decompression, i.e., surgical fasciotomy. Appropriately-timed fasciotomy makes the difference between amputation and a viable extremity.

REDEBRIDEMENT AND WOUND CLOSURE

After the wound has been debrided, irrigated, and appropriately dressed, it is not inspected for 4-10 days unless the clinical course dictates an earlier appraisal. Intervening dressing changes are not indicated unless the clinical course indicates that there is continued hemorrhage, vascular changes, or infection. This inspection of the wound should be performed in the operating room. At that time, if there is significant devitalized tissue or purulent drainage, redebridement is accomplished. If the wound is clean and without evidence of infection, a delayed primary closure is performed. The wound should not be closed with undue tension, nor with extensive development of flaps. Wounds that cannot be easily closed should be dressed for subsequent split-thickness skin grafting at the next echelon of surgical care. Any wound closed by the delayed primary technique should be followed carefully for evidence of inflammation or infection. If signs of infection develop, the wound should be reopened. If the patient is not to

be retained at the forward hospital so that he can be followed for several days, it is advisable to defer delayed primary closure to those personnel in the evacuation chain who are able to provide proper continuing follow-up.

INFECTED BONE OR JOINT INJURIES

Early medical evacuation from the battlefield provides access to the casualty before frank infection has developed. However, if the tactical situation is such that infection has already occurred, emergency operation is still indicated. Wide exposure is accomplished for excision of devitalized tissue, removal of foreign bodies, and drainage of purulent material. The wound is irrigated copiously, and systemic broad-spectrum antibiotics are utilized until an infecting organism has been identified and sensitivities determined. The use of suction irrigation as a technique in infected fractures and septic joints is somewhat controversial. Caution must be used to avoid systemic toxicity when continuous antibiotic irrigation is employed.

SPRAINS AND DISLOCATIONS

Ligamentous injuries (sprains) are frequently encountered in the combat zone. These injuries do not have the inherent seriousness of penetrating missile injuries of joints as previously described, but they may be severe and disabling in terms of combat effectiveness. Support of the joint by bandaging, splinting, or casting usually will facilitate healing. The use of immobilization and casting, particularly for lower extremity injuries, may allow the individual soldier to return to limited duty.

Closed dislocations of joints, which are encountered less frequently than sprains, are usually more disabling. Dislocated joints should be considered a surgical emergency and the joint should be reduced as soon as possible. This reduction can usually be carried out without the administration of anesthetic, with the possible exception of the hip and knee joint dislocations. The distal neurovascular status of the extremity should always be checked both before and after reduction. The post-reduction radiographs are extremely important to insure complete reduction and to rule out the presence of iatrogenic fractures.